



International Journal of Allied Medical Sciences and Clinical Research (IJAMSCR)

ISSN:2347-6567

IJAMSCR |Volume 4 | Issue 1 | Jan-Mar - 2016
www.ijamscr.com

Research article

Medical research

Unusual incidental findings of routine histopathological examination of appendectomy specimens- a 2-year retrospective analysis with review of the literature

Divya Rabindranath, Azka Anees Khan, Hena Ansari, Senthil P.

Department of Pathology, Jawaharlal Nehru Medical College, Aligarh Muslim University, India.

Junior Resident, Department of Pathology, J.N. Medical College, Aligarh, India.

Assistant Professor, Department of Pathology, J.N. Medical College, Aligarh, India.

Junior Resident, Department of Pathology, J.N. Medical College, Aligarh, India.

***Corresponding author: Dr. Divya Rabindranath**

Email Id: divy30@hotmail.com

ABSTRACT

Objective

To review the diagnosis of all patients that underwent appendectomy at our institute over a period of 2 years, and to correlate the histopathological diagnosis with the clinical diagnosis in each case.

Material and methods

This was a 2 year retrospective study including all patients that presented to our institute with acute appendicitis and underwent appendectomy for the same, over the period of 2 years. Cases that underwent appendectomies as an incidental procedure during some other operation were excluded.

Results

A total of 325 cases were included in our study. Majority of these cases (300/325, 92.3%) showed features of appendicitis (acute, subacute, chronic, recurrent or resolving). 17 (5.2%) of the cases were labeled as normal while the remaining cases (8/325, 2.5%) had some unexpected abnormal findings including 2 cases of mucocele and 1 case each of granulomatous appendicitis, eosinophilic obliterative appendicitis, well differentiated mucinous cystadenocarcinoma, well differentiated adenocarcinoma, carcinoid and low grade appendiceal mucinous neoplasm with pseudomyxoma peritonei.

Conclusion

Though majority of cases had the usual features, a few of these had important incidental diagnoses which were not suspected preoperatively or even intraoperatively by the surgeon. These findings support the opinion that all appendectomy specimens should be routinely sent for histopathological examination, which is unfortunately not the scenario in many centers across India.

Keywords: Appendicitis, Mucocele, Adenocarcinoma, Pseudomyxoma Peritonei, Appendectomy.

INTRODUCTION

Acute appendicitis is widely known to be the most common general surgical emergency [1]. However, its incidence in India is not clear, as no community based study to calculate the same has been conducted here, to the best of our knowledge. Data from the United States point to values of 1.5 and 1.9/1000 in males and females respectively [2].

Acute appendicitis was first reported as a distinct entity by Fitz in 1886 [3]. The histological criterion for the diagnosis of acute appendicitis has been defined by neutrophilic infiltration of the muscularis propria [4]. Although it is known to be one of the most common surgical emergencies; the preoperative clinical diagnosis of appendicitis is correct in only 60-80% of the cases [5]. It has been shown that approximately 20% of those undergoing appendectomies are not found to have acute appendicitis at surgery [6]. This finding has been observed to be more common in females than males with a ratio approaching 3:1 in the 15–19 age groups [7].

The practice of sending all appendix specimens for routine histopathological examination depends on the concerned institution and is variable. Matthyssens et al are against this policy and suggest that appendices should be sent for examination only if there is an obvious macroscopic abnormality at surgery [8]. They justify their opinion by the rarity of aberrant findings, together with the significant costs of specimen processing. However, a number of other papers have found such aberrant incidental findings to be more common, and suggest that failure to histopathologically examine all appendices would lead to many significant pathologies being missed and cause an impact on patient management [9-14]. There is no authoritative data or previous studies which deal with this issue in India. Hence, a query still remains whether this policy should be adhered to in poor resource countries like India also. Keeping in mind the above facts, we undertook this study to shed some light on this topic by evaluating the current scenario concerning this issue in India.

MATERIAL AND METHODS

We retrospectively studied all cases that underwent appendectomy at our institution after being diagnosed with acute appendicitis. The period of study was from 1st August 2012 to 31st July 2014. Patients undergoing appendectomy for some other clinical diagnosis, and those in which appendix was removed incidentally as a part of some other operation were not included in the study.

The slides of all the patients were reviewed and those with incidental aberrant findings were studied in detail. Patients' age and sex were also noted, and operative details were analyzed to determine whether the final histopathological diagnosis was suspected by the surgeon intraoperatively.

RESULTS

A total of 325 patients were included in our study, 191(58.7%) of whom were males and 134 (41.2%) were females. All of them had a diagnosis of acute appendicitis based on clinical and laboratory data (Fig.1). The patients ranged in age from 8 to 66 years with most of them being in the 21 to 30 year age group. The mean age for having an appendectomy was 26 years with a standard deviation of 9.28. Table 1 shows the age and sex distribution of all patients. About 57% of those having a normal appendix were females with a mean age of 21 years.

17 (5.2%) of the cases submitted were found to be normal on histopathological examination, 300 (92.3%) were found to have features of appendicitis, while 8 (2.5%) revealed some other incidental abnormal findings. These included 2 cases of mucocele (Fig.2) and 1 case each of granulomatous appendicitis (Fig.3), eosinophilic obliterative appendicitis (Fig.4), well differentiated mucinous cystadenocarcinoma (Fig.5), well differentiated adenocarcinoma (Fig.6), carcinoid (Fig.7) and low grade appendiceal mucinous neoplasm (LAMN) with pseudomyxoma peritonei (Fig.8). Table 2 demonstrates the histopathological diagnosis of all the cases.

Table 1: Age and sex distribution of all patients

Age (years)	Males (no. of cases)	Females (no. of cases)	Total
0- 10	5	2	7
11- 20	55	32	87
21- 30	100	72	172
31- 40	26	24	50
41- 50	2	2	4
51- 60	2	1	3
61- 70	1	1	2
Total	191 (58.7%)	134 (41.2%)	325 (100%)

Table 2: Analysis of histopathological findings of appendectomy specimens

DIAGNOSIS	NO. OF CASES	PERCENTAGE
Normal	17	5.2%
Appendicitis:		
• Acute appendicitis	188	57.8%
• Acute appendicitis + periappendicitis	54	16.6%
• Subacute appendicitis	8	2.5%
• Chronic appendicitis	26	8.0%
• Chronic obliterative appendicitis	9	2.8%
• Recurrent appendicitis	10	3.1%
• Resolving appendicitis	5	1.5%
	300	92.3%
Other incidental findings:		
• Granulomatous appendicitis	1	0.3%
• Eosinophilic appendicitis with obliteration	1	0.3%
• Mucocele	2	0.6%
• LAMN + pseudomyxoma peritonei	1	0.3%
• Well differentiated mucinous cystadenocarcinoma	1	0.3%
• Well differentiated adenocarcinoma	1	0.3%
• Carcinoid	1	0.3%
	8	2.5%

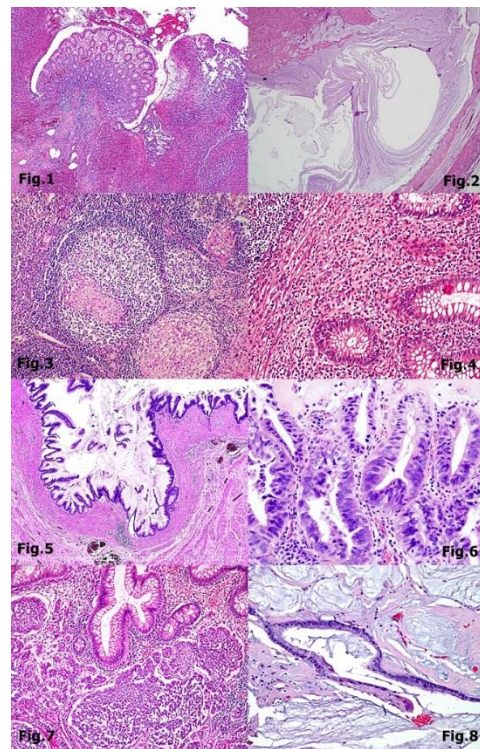


Fig.1

Acute appendicitis- Mucosa shows ulceration, necrosis and abundant neutrophilic infiltrate (H&E X10X).

Fig.2

Mucocoele- Dilated appendix filled with mucinous secretion and thin appendiceal wall (H&E x40X).

Fig.3

Granulomatous appendicitis- caseating granulomatous centre surrounded by epitheloid cells, lymphocytes, histiocytes and giant cell seen (H&E X40X)

Fig.4

Eosinophilic appendicitis- Showing diffuse eosinophilic infiltrate in the lamina propria (H&E X 40X).

Fig.5

Mucinous cystadenocarcinoma- Cyst lined by typical pseudostratified columnar cells with elongated, crowded, hyperchromatic nuclei with atypia and scattered goblet cells with mucin in cavity (H&E X 40X).

Fig.6

Adenocarcinoma- Well differentiated malignant glands infiltrating lamina propria with atypia (H&E X40X).

Fig.7

Carcinoid- consisting of monotonous population of cells arranged in insular and trabecular patterns in the lamina propria of the appendix (H&E X 40X).

Fig.8

Low grade appendiceal mucinous neoplasm with pseudomyxoma peritonei- Section from the omentum showing pools of extracellular mucin associated with fibrosis and rare glands lined by simple mucinous epithelium without atypia (H&E X40x).

DISCUSSION

Our study reiterated the widely known fact that acute appendicitis is a disease of young age group with a slight male preponderance [4]. We also found that a diagnosis of normal appendix on histopathological examination is more common in younger females. Such findings have been reported by previous researchers also [16]. Previous researchers have suggested that all histopathological specimens should be audited to improve clinical evaluation particularly in females [17]. At the earliest stages of appendicitis, only scant neutrophilic exudates may be found in the wall of the appendix. Congested submucosal vessels are often seen along with perivascular

neutrophilic infiltrates and dull serosa. The appendix may be reported by the pathologist at this stage to be normal, whereas in fact the lesion is just beginning at the earliest stage [4]. Njeze et al suggest that this phenomenon may account for some of the so called false negative cases of appendix examined after surgery [15]. This hypothesis also provides a possible explanation for the common observation of such patients getting symptomatic relief after appendectomy [16].

The histopathological examination of the appendix has been observed to serve two purposes [16]. Firstly, it allows the diagnosis of acute appendicitis to be confirmed. Secondly, histopathological examination may disclose additional pathologies that may not be evident intraoperatively which may impact patient management [10].

There are very few studies which highlight the benefits of analyzing appendectomy specimens, and even fewer so addressing this issue in India. One such rare study was by Geetha et al where the authors ascribed four (1.2%) of the unusual lesions to neoplasms (adenocarcinoma and carcinoids) while mucocele accounted for two (0.6%) of the observed pathologies. Tuberculosis with enterobias vermicularis were found to be responsible for one (0.3%) of the lesions while xanthogranulomatous appendicitis was found in one case (0.3%) (37). Because of the lack of sufficient data on the subject, the practice of sending appendectomy specimens for histopathological examination is highly variable. Some centers (including ours) send all resected appendices for histopathological analysis, while others send specimens only if they appear macroscopically abnormal at the time of surgery [8]. The latter practice could potentially be detrimental to patient management. Polat et al have shown in their study that the intra-operative detection rate for all types of appendiceal tumors is less than 50% [10]. Similarly, Deans et al suggested that surgeons missed abnormal pathological findings in 10 out of 13 patients, the majority of which required further investigation or treatment [13]. Hence, preliminary data suggest that it would be unwise to rely solely on the intraoperative findings to decide whether to send a specimen for histopathological examination or not. Another important factor that comes up while considering this issue in India is the cost versus benefit ratio. A question still remains whether it is

worthwhile to follow such a practice in poor resource countries like India. We describe our findings here in order to form an opinion about the issue at hand.

All of the cases included in our study had been clinically diagnosed as acute appendicitis and were operated for the same. On histopathology, 17 (5.2%) cases were found to be normal. 300 (92.3%) showed features of acute or chronic appendicitis while 8 (2.5%) cases showed incidental abnormal findings which were deemed clinically significant and led to further patient investigation and management. None of the incidental abnormal findings discovered on histopathology were suspected by the surgeon intraoperatively. Therefore, it stands to reason that these 8 cases would have been missed had the surgeon not sent these specimens for histopathological examination. This number, although small, is still significant when one takes into account the significant impact these findings had on patient management.

Our study included 45 (13.8%) cases of chronic, chronic obliterative and recurrent appendicitis combined. Although these diagnoses are quite rare and were different from the clinical diagnosis, they did not lead to any change in further patient management. Chronic appendicitis has been reported to have an incidence of about 1.5 to 10% of all appendix inflammations [30,31]. The term is in fact, disputed clinically and pathologically. Falk et al reported that fibrosis, chronic inflammatory infiltrates, and neural cell proliferation are the most specific pathologic features in chronic appendicitis [32]. Edino et al. [36] in their study reported 17% cases of chronic fibrosing appendicitis. In contrast, Lai et al reviewed 16 cases having appendicitis with symptoms over few weeks, and found no chronic inflammation on histopathology of all the cases. They suggested that it is better to use the term "recurrent appendicitis" instead of "chronic appendicitis"[33]. We, however, found that cases of chronic, chronic obliterative and recurrent appendicitis showed distinct histopathological features; and hence they were grouped separately.

Our study included 1(0.3%) case of eosinophilic appendicitis with obliteration. Eosinophilic appendicitis is characterized by lack of neutrophils, and eosinophilic infiltration in muscle layer with odema separating muscle fibers (the Eosinophil - Edema lesion) or (E-E lesion) [34]. This disease may be associated with helminthes infection in the

vein of schistosomiasis, strangyloides or enterobius. It has been suggested that the disease might be triggered by Type I Hypersensitivity [35]. It could also be part of eosinophilic gastroenteritis which is a rare and heterogeneous condition characterized by patchy or diffuse eosinophilic infiltration of gastrointestinal (GI) tissue, first described by Kaijser in 1937. The diagnosis of eosinophilic appendicitis led to a diligent search for the cause in our patient but none could be found.

Another important incidental diagnosis in our study was granulomatous appendicitis. Incidence of this rare condition has been reported as 0.14% to 0.3% in Western countries and as 1.3% to 2.3% in underdeveloped countries [27, 29]. It can be caused by various infectious and noninfectious factors. Systemic conditions, such as Crohn's disease and sarcoidosis, may be associated with granulomatous inflammation of the appendix. However, infectious causes like Mycobacterium tuberculosis, Yersinia spp, blastomycosis, Schistosoma spp, Actinomyces spp, Campylobacter spp, and Histoplasma capsulatum form a much more important cause in our country [27, 29]. Since TB is endemic in our country, our case was also suspected to suffer from intestinal tuberculosis. Patient was subsequently investigated for the same and our suspicions were found to be correct.

Tuberculosis usually presents in a way that is clinically indistinguishable from appendicitis making histopathological examination the only option for making definitive diagnosis [15]. The reported incidence of appendicular TB varies from 0.1% to 3.0% among all appendectomies performed. An accurate diagnosis is usually established only after histopathological examination of a specimen. Some studies report that no further treatment after appendectomy is necessary for primary appendicular disease. In contrast, Jones et al described a case of appendicular TB in their study who subsequently underwent right hemicolectomy for treatment. Hence, no consensus has been reached yet about the treatment of appendicular TB [16, 27, 28].

Acute appendicitis may be the mode of presentation of appendix neoplasms particularly adenocarcinoma [9] as was also seen in our study. One case that was suspected to be acute appendicitis was finally revealed to have adenocarcinoma on histopathological examination. This particular patient underwent further

investigations and subsequently had right hemicolectomy.

Carcinoids are the most common tumors of appendix and are typically small, firm, circumscribed yellow brown lesions [8]. An appendiceal carcinoid tumor is found in 0.3%-2.27% of patients undergoing an appendectomy [19]. It has been suggested that carcinoid tumors may present as appendicitis because of luminal obstruction or elevated levels of 5 hydroxy tryptamine, histamine and kinin as these are all potent mediators of inflammation [18]. Characteristics of appendiceal carcinoids predicting aggressive behavior include tumor size, histological subtype, and mesoappendiceal involvement. The tumors are smaller than 1 cm in 70%-95% of cases [19], including ours. Such small tumors are easily missed on gross examination intraoperatively. The calculated risk of metastasis from tumors 1 cm or smaller is reported to be nearly zero and therefore may be managed with a simple appendectomy. An increase in metastasis risk of up to 85% occurs with a tumor double the size or larger. An appendiceal carcinoid tumor larger than 2 cm should be managed with a formal right hemicolectomy [19, 20]. Since our particular case was about 1 cm in size, no further management was needed. However, the patient was kept on close follow up following the diagnosis of carcinoid tumor.

Our study also included two cases of mucocele. A mucocele of the appendix denotes an obstructive dilatation of the appendiceal lumen due to abnormal accumulation of mucus, which may be caused either by a retention cyst, endometriosis, mucosal hyperplasia, cystadenoma, or a cystadenocarcinoma. The incidence of mucocele has been reported to range from 0.2% to 0.3% of all appendectomy specimens. Mucoceles are often asymptomatic and discovered only as incidental findings at appendectomy, or during laparotomy for another indication or at histological examination of an operative specimen. However, they may also be diagnosed clinically from features of acute appendicitis. Confirmative diagnosis of mucocele and its cause is possible only after histopathology. Appendectomy is the treatment of choice for mucinous cystadenoma, whereas a cystadenocarcinoma requires a right hemicolectomy. Because of the high association of mucinous cystadenoma with colon and ovarian malignancy, follow-up CT, US, and colonoscopy

examinations must be performed during the postoperative period [21, 22].

Another important case included in our study was a mucinous cystadenocarcinoma. These are rare neoplasms and present as acute appendicitis. Hence, they can be diagnosed only after histopathological examination of the specimen. Also, they are usually associated with a second GI malignancy; hence their early detection becomes all the more important for adequate patient management. [23,24,25,26]. Our case of mucinous cystadenocarcinoma subsequently underwent right hemicolectomy after diagnosis on histopathology.

Our study included a single case of low grade appendiceal neoplasm (LAMN) with pseudomyxoma peritonei. It has been reported to be a rare tumor and its preoperative diagnosis is difficult despite extensive investigations. Patients with LAMN can initially present with acute abdomen. The actual diagnosis is usually made intraoperatively or during histopathological examination of the resected specimen. The treatment remains appendectomy with mesoappendix excision in cases limited to the appendix. Any invasion beyond the appendix would need right hemicolectomy. Although surgical treatment is straightforward, proper management of the incidentally found lesion requires understanding of the potential complications of widespread peritoneal disease. It should be kept in mind that LAMN may coexist with other neoplasms, and follow-up colonoscopy and pelvic examination is warranted for the high association with other colon and ovarian malignancies [38].

Hence, our study demonstrated that histopathological examination led to the incidental diagnosis of many important lesions that would

have been otherwise missed by the surgeon. These diagnoses led to significant effect on patient management. These included conditions like LAMN and mucinous cystadenocarcinoma which have a high risk of association with other neoplasms. Hence, their diagnosis is imperative for adequate patient management. Also, few conditions can be first diagnosed in appendix only, like granulomatous appendicitis (due to tuberculosis or crohn's disease), cancers like carcinoid and adenocarcinoma. Thus, such incidental detection can lead to early treatment of these conditions. It becomes obvious from the above discussion that it is highly beneficial to send all appendectomy specimens for histopathological examination. When we weigh the cost of the procedure against the possible benefits, it becomes clear that the benefit far outweighs the cost in this situation. Early diagnosis and treatment of a lesion would prevent the added costs the patient would have to bear if the diagnosis was late and the disease had spread to other organs.

CONCLUSION

Although most of the cases in our study had usual findings on histopathological examination (acute and chronic appendicitis), few showed incidental abnormal findings which led to change in the clinical diagnosis and course of patient management. The benefit of routine histopathological examination was found to outweigh the cost of the procedure. Hence, it is highly recommended that all appendectomy specimens are submitted for histopathological examination, even in a poor resource country like India.

BIBLIOGRAPHY

- [1]. Marudanayagam R, Williams GT, Rees BI. Review of pathological results of 2660 appendectomy specimens. *J Gastro* 2006; 41: 745-9.
- [2]. Kalan M, Talbot D, Conifer WJ, Rich AJ. Evaluation of modified Alvarado score in diagnosis of acute appendicitis; A prospective study. *Ann R Coll Surg* 1994; 76: 418-9.
- [3]. John E Loveland. Reginald Fietz. The exponent of appendicitis. *Yale J. of biol med.* July 1937; 9(6):509.b1-520.
- [4]. Chen L., Crawford J.M. The Gastrointestinal tract. In Robbins Pathological basis of disease 7th Edition, 2005. Saunders an imprint of Elsevier Inc. Philadelphia. 870-872
- [5]. Fergusson JAE, Hitos K, Simpson E. Utility of white cell count and ultrasound in the diagnosis of acute appendicitis. *ANZ J Surg* 2002; 72: 781-5

- [6]. McCallion J, Canning GP, Knight PV, McCallion JS: Acute appendicitis in the elderly: a 5 year retrospective study. *Age Ageing* 1987; 16:256-260.
- [7]. Primates P, Goldacre MJ: Appendectomy for acute appendicitis and for other conditions: An epidemiological study. *Int J Epidemiol* 1994; 23(1):155-160
- [8]. Matthyssens LE, Ziol M, Barrat C, Champault GG: Routine Surgical Pathology in General Surgery. *Br J Surg* 2006; 93:362-368
- [9]. Chan W, Fu KH: Value of Routine Histopathological examination of appendices in Hong Kong. *J Clin Pathol* 1987; 40:429-433.
- [10]. Duzgun AP, Moran M, Uzun S, Ozmen M, Ozer VM, Seckin S, Coskun F: Unusual findings in appendectomy specimens: Evaluation of 2458 cases and review of the literature. *Indian J Surg* 2004; 66(4):221-226.
- [11]. Nemeth L, Reen DJ, O'Briain D, McDermott M, Pui P: Evidence of an Inflammatory Pathologic Condition in "Normal" Appendices following Emergency Appendectomy. *Arch Path Lab Med* 2001; 125(6):759-764.
- [12]. Modlin IM, Sandor A: An analysis of 8305 cases of carcinoid tumours. *Cancer* 1997; 79(4):813-829.
- [13]. Deans GT, Spence RA: Neoplastic lesions of the appendix. *Br J Surg* 1995; 82(3):299-306.
- [14]. Rutledge RH, Alexander JW: Primary appendiceal malignancies: rare but important. *Surgery* 1993; 113(5):594.
- [15]. Njeze G. E., Nzegwu M.A, Agu K.A., Ugochukwu A I and Amu C. A Descriptive Retrospective Review of 152 Appendectomies in Enugu Nigeria from January 2001 to 2009. *Adv. Biores.* 2011; 2 [2]: 124-126.
- [16]. Zulfikar I, Khanzada T.W., Sushel C. Samada. A Review of the pathologic diagnoses of appendectomy specimens. *Annals* 2009; 15(4): 168-170
- [17]. Sitara AS, Junaid TA. Diagnostic accuracy in Appendicitis, A histopathology study. *Med Principles Pract* 2001; 10: 182-6.
- [18]. Cortina R, McCormick J, Kolm P, Perry RR. Management and prognosis of adenocarcinoma of the appendix. *Dis Colon Rectum* 1995; 38: 848-52
- [19]. Sieren LM, Collins JN, Weireter LJ, Britt RC, Reed SF, Novosel TJ, Britt LD. The incidence of benign and malignant neoplasia presenting as acute appendicitis. *Am Surg* 2010; 76: 808-811
- [20]. Guraya SY, Khairy GA, Ghallab A, Al-Saigh A. Carcinoid tumors of the appendix. Our experience in a university hospital. *Saudi Med J* 2005; 26: 434-437
- [21]. Caliřkan K, Yildirim S, Bal N, Nursal TZ, Akdur AC, Moray G. Mucinous cystadenoma of the appendix: a rare cause of acute abdomen. *Ulus Travma Acil Cerrahi Derg* 2008; 14: 303-307
- [22]. Kiyak G, Celik A, Sarikaya SM. Mucocele of the appendix due to mucinous cystadenoma. *J Pak Med Assoc* 2009; 59: 336.
- [23]. Bucher P, Mathe Z, Demirag A, Morel P. Appendix tumors in the era of laparoscopic appendectomy. *Surg Endosc* 2004; 18: 1063-1066
- [24]. Graham RP, Williams NP, West KA. Primary epithelial tumours of the appendix in a black population: a review of cases. *World J Gastroenterol* 2009; 15: 1472-1474
- [25]. Ma KW, Chia NH, Yeung HW, Cheung MT. If not appendicitis, then what else can it be? A retrospective review of 1492 appendectomies. *Hong Kong Med J* 2010; 16: 12-17
- [26]. Leanza S, Bekheit M, Coco D, Bellia A, Ferrara F, Sarva S, Pappalardo A, Piazza L. Carcinoma of the appendix and its natural history in relation to surgical management. A case report. *Chir Ital* 2009; 61: 597-600
- [27]. AbdullGaffar B. Granulomatous diseases and granulomas of the appendix. *Int J Surg Pathol* 2010; 18: 14-2
- [28]. Jones AE, Phillips AW, Jarvis JR, Sargen K. The value of routine histopathological examination of appendectomy specimens. *BMC Surgery* 2007; 7:17.
- [29]. Tucker ON, Healy V, Jeffers M, Keane FB. Granulomatous appendicitis. *Surgeon* 2003; 1(5):286–289
- [30]. Mattei P, Sola JE, Yeo CJ. Chronic and recurrent appendicitis are uncommon entities often misdiagnosed. *J Am Coll Surg* 1994; 178: 385-9
- [31]. Savrin RA, Clausen K, Martine EW, Cooperma M. Chronic and recurrent appendicitis. *Am J Surg* 1979; 137: 355-7.

- [32]. Falk S, Schutze U, Guth H, Stutte HJ. Chronic recurrent appendicitis. A clinicopathologic study of 47 cases. *Eur J Pediatr Surg* 1991; 1: 277-81.
- [33]. LAI, DH, CHUANG, CH, YU, JC et al. Chronic or recurrent appendicitis?. *Rev. esp. enferm. dig.*2007; 99(10):613-615.
- [34]. KP Aravindan, Deepthy Vijayaraghavan, Marie Therese Manipadam. Significance of eosinophil - Edema lesion. *Indian J Pathol Microbiol* 2010; 53:258-61.
- [35]. Aravindan KP. Eosinophils in acute appendicitis: Possible significance. *Indian J Pathol Microbiol* 1997; 40:491-8
- [36]. Edino ST, Mohammed AZ, Ochicha O, Anumah M. Appendicitis in Kano, Nigeria: A 5 year review of pattern, morbidity and mortality. *Annals of African Medicine* 2004; 3(1): 38-41.
- [37]. Geetha R.L., Anitha.M.R, Vijayanath.V, Kavitha G.U.V. Spectrum of Histopathological lesions in appendix in a tertiary care centre at Bangalore. *Journal of Medical Research and Practice*2012; (1)
- [38]. Wang KC, Chen CH, Chen CZ, Huang HY, You JJ, Lin TC. *J Soc Colon Rectal Surgeon (Taiwan)*2012;23:183-189

How to cite this article: Divya Rabindranath, Azka Anees Khan, Hena Ansari, Senthil P, Unusual incidental findings of routine histopathological examination of appendectomy specimens- a 2-year retrospective analysis with review of the literature. *Int J of Allied Med Sci and Clin Res* 2016; 4(1):90-98.

Source of Support: Nil. **Conflict of Interest:** None declared.