



## International Journal of Allied Medical Sciences and Clinical Research (IJAMSCR)

ISSN:2347-6567

IJAMSCR | Volume 4 | Issue 3 | July - Sep - 2016  
www.ijamscr.com

Research article

Medical research

### Morphological study of shape of glenoid cavity of scapula

Rachna Agrawal<sup>\*1</sup>, Sangita chauhan<sup>\*2</sup>, Sunny yadav<sup>\*3</sup>, Arpita gupta<sup>\*4</sup>, Manish singhal<sup>\*5</sup>

<sup>1</sup>Senior demonstrator, SMS medical college, Jaipur.

<sup>2</sup>Senior professor, dept. of anatomy, SMS medical college, Jaipur.

<sup>3</sup>Assistant professor, Apollo institute of medical sciences, Hyderabad.

<sup>4</sup>Senior resident, dept. of anatomy, Vardhman medical college, New Delhi.

<sup>5</sup>Assistant professor, department of pathology, SMS medical college, Jaipur.

Corresponding author: Rachna A

#### ABSTRACT

##### Objectives

The scapula is one of the most interesting bone of the human skeleton because it presents many variations. This variability in glenoid affects Prosthesis design, Instrumentation, and Intraoperative implantation techniques. The anatomical basis and variations of shape and size of glenoid cavity of scapula is very important to understand rotator cuff disease, shoulder dislocation and to decide the proper size of the glenoid component in the shoulder arthroplasty.

##### Method

This study was done on 131 dry, unpaired adult human scapulae. Out of the 131 scapulae, 64 were from the right side, and 67 were from the left. Only the bones with clear and intact glenoid cavity with complete ossification were used. We got a tracing of the shape of the glenoid cavity on the white sheet.

##### Result

In our study, we recorded 14.06% of the right and 29.86% of left glenoids were inverted comma shaped with a distinct notch. The pear shaped glenoids were 50.00% on the right side and 44.78% on the left side with an indistinct notch. On the right side 35.94% were oval and on the left side 25.37% were oval without any recognisable notch. Combined average of both sides of the glenoid 30.53% were oval shape, 47.33% was pear shape and 22.14% was inverted comma shape glenoid found in our study.

In our study two type notch found in the pear shape glenoid. Single notch found in 85.11% on the left side and 87.50% on the right side, while the double notch found in 14.09% in left side and 12.50% in right side. This suggests no significance of number of notches in our study.

The percentage of glenoids with both indistinct and distinct notch was 50% on the right side and 70.15% on the left side, which was found statistically significant in our study. This suggests that there is a significant difference in the presence of a notch on the right and left side.

**Keywords:** Glenoid cavity; Total shoulder arthroplasty; Glenoid Notch.

## INTRODUCTION

The shoulder joint is the most frequently dislocated joints in the body<sup>1</sup>. Glenoid cavity present on the upper and lateral angle of the scapula. It is shallow, pyriform articular surfaces which articulate with the head of the humerus and forms the shoulder joint<sup>2</sup>.

Glenoid rim presents a notch in its upper and front part<sup>3</sup>. The notch is better marked in the early state of the bone, indicating the junction of the “coracoid” and “scapular” parts of the articular surface, and the part above the notch has a separate center of ossification<sup>3</sup>. Anetzberger and Putz, classified the shape of the glenoid cavity as teardrop-shaped glenoid cavity, type IA and IB, with and without a notch respectively, from an elongated oval shape type II<sup>4</sup>.

The morphology of the glenoid cavity is highly variable. The shape of glenoid also changes from superior to inferior. Inui et al. have shown that the superior part of glenoid surface is retroverted and that the inferior portion may be anteverted. They showed the upper aspect has a large radius of curvature, is convex, and subsequently, becomes flat and then concave in the lower portion with a small radius of curvature<sup>5</sup>.

Burkhart and De Beer, described an inverted-pear glenoid, in which a normally pear-shaped glenoid lost enough anterior-inferior bone to assume the shape of an inverted pear<sup>6</sup>.

A better knowledge of the anatomy of Scapula can be used to adjust the design and placement of the reverse prosthesis and minimize Scapular notching.

## MATERIAL AND METHODS

A study was done on 131 dry unpaired human scapula of adult individual available at Department

This is shown in the following table:

TOTAL SCAPULAE	RIGHT SIDED SCAPULAE	LEFT SIDED SCAPULAE
131	64	67

### Morphological variations of glenoid cavity

In the presence or absence of notch there are many types of glenoid cavity which are following:

1. **Oval shape glenoid** –in this type notch is absent.

of Anatomy, S.M.S. Medical College, Jaipur. Out of the 131 scapulae, 64 were from the right side, and 67 were from the left. Only adult dry Scapula with clear and intact glenoid cavity with complete ossification are included. But the exact ages and gender of the scapulae were not known. The bones were isolated and inspected macroscopically. Scapula with a fractured glenoid cavity, glenoid labrum is attached to glenoid cavity, pathological scapula and children’s scapula were not included.

### Method of recording the shape of the glenoid cavity

A white sheet was placed on the glenoid cavity of scapula and held firmly in position to trace the shape of the glenoid cavity. The side of the point of a lead pencil will be rubbed along the rim of the glenoid cavity to get a tracing of the shape of the glenoid cavity on the white sheet and morphological variations was seen.

The following parameters of the glenoid cavity were studied.

### Shape of the glenoid cavity

A shape made by the slightly raised rim of the glenoid cavity.

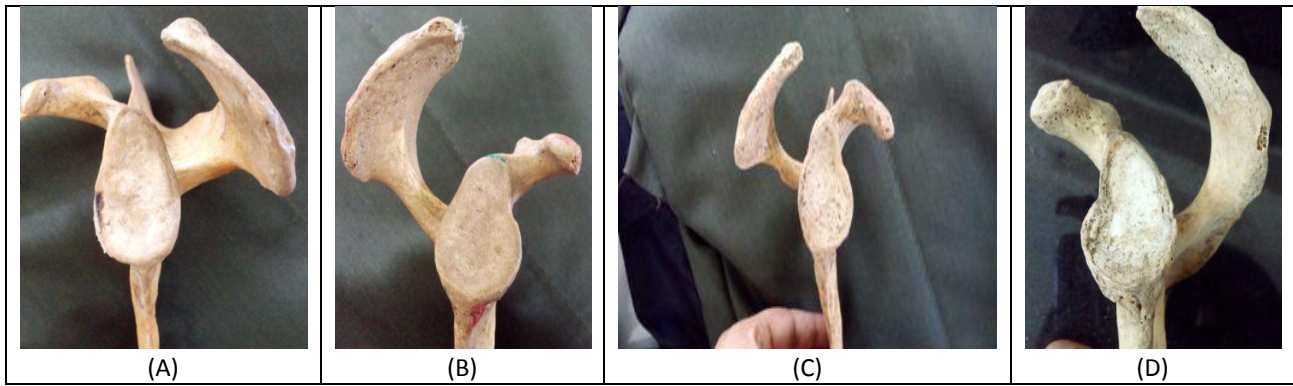
### Notch of glenoid cavity

The notch is present on the anterior rim of the glenoid. In some glenoid notch is present on both anterior and posterior rim.

## OBSERVATIONS AND RESULTS

All the morphological variations of the glenoid cavity of the scapula are evaluated by dividing the data in 2 categories based on site.

2. **Pear shape glenoid** –in this type notch is present. Notch could be single (the notch on anterior rim) or double (notches on both rims). Here the notch is indistinct type.
3. **Inverted comma shape glenoid** – in this type notch is present, which is distinct in type.



**Fig. :** Photograph showing the various shapes of the glenoid cavity

(A) Oval shape glenoid cavity, (B) Pear shape glenoid with indistinct single notch, (C) Pear shape glenoid with indistinct double notch, (D) Inverted comma shape glenoid with distinct notch

**Comparison of different morphological parameters of glenoid cavity on the basis of side**

**Table-1:** Assessment of a morphological parameter (SHAPE) of right and left Glenoid Cavity

Shape	Scapula				Total	
	Left		Right		No.	%
	No.	%	No.	%		
Oval	17	25.37	23	35.94	40	30.53
Pear	30	44.78	32	50.00	62	47.33
Inverted Comma	20	29.86	9	14.06	29	22.14

**Table 2:** Assessment of a morphological parameter (NOTCH) of right and left Glenoid Cavity

Notch	Scapula				Total	
	Left		Right		No.	%
	No.	%	No.	%		
Absent	20	29.85	32	50.00	52	39.69
Single Notch	40	59.70	28	43.75	68	51.91
Double Notch	7	10.45	4	6.25	11	8.40

**Table 3:** Assessment of a morphological parameter (PRESENCE OF NOTCH) of right and left Glenoid Cavity

Notch	Scapula				Total	
	Left		Right		No.	%
	No.	%	No.	%		
Absent	20	29.85	32	50.00	52	39.69
Present	47	70.15	32	50.00	79	60.31

**Table 4: Assessment of a morphological parameter (NUMBER OF NOTCH) of right and left Glenoid Cavity**

Notch	Scapula				Total	
	Left		Right			
	No.	%	No.	%	No.	%
<b>Single Notch</b>	40	85.11	28	87.50	68	86.08
<b>Double Notch</b>	7	14.89	4	12.50	11	13.92

**Table 5: COMPARISON OF SHAPE OF GLENOID CAVITY FROM VARIOUS AUTHORS**

Observers	No. of Specimens	Oval shape glenoid	Pear shape glenoid	Inverted shape glenoid
Prescher and Klumpen 1997	-	45%	-	-
Coskun et al (2006)	90	72%	28%	-
Mamatha et al (2009)	Right-98 Left-104	20% 24%	- -	- -
Hina B. Rajput et al (2012)	Right-43 Left-57	16% 15%	49% 46%	35% 39%
Kavita Pauja et al (2013)	Right-67 Left-62	30%	58%	11%
Our study(2015)	Right-64 Left-67	35.94% 25.37%	50% 44.78%	14.06% 29.86%

## DISCUSSION

In the current study, the incidence of various shapes of the glenoid cavity has been measured and compared with other studies. Various types of glenoid cavity based on their shape were observed in the current study. The percentage of occurrence of various shapes of the glenoid cavity was recorded. In our study, recorded 14.06% of the right and 29.86% of left glenoids were inverted comma shaped with a distinct notch. The pear shaped glenoids were 50.00% on the right side and 44.78% on the left side with an indistinct notch. On the right side 35.94% were oval and on the left side 25.37% were oval without any recognisable notch.

Combined average of both sides of glenoid 30.53% was oval shape, 47.33% was pear shape and 22.14% was inverted comma shape glenoid found in our study. In our study two type notch found in the pear shape glenoid. Single notch found in 85.11% in left side and 87.50% on the right side, while the double notch found in 14.09% in left side and 12.50% in right side. This suggests no significance of number of notches in our study.

The shape of the glenoid cavity was found the oval type in 30% of the samples and pear type 58%,

and comma shape in 11% of the samples in study of Kavita Pahuja et al<sup>7</sup>.

In study of Hina B. Rajput<sup>1</sup>, recorded 35% of the right and 39% of left glenoids were inverted comma shaped with a distinct notch. The pear shaped glenoids were 49% on the right side and 46% on the left side with an indistinct notch. On the right side 16% were oval and on the left side 15% were oval without any recognisable notch. This suggests that there is no significant difference in the presence of a notch on the right and left side.

The percentage of glenoids with both indistinct and distinct notch was 50% on the right side and 70.15% on the left side in our study. On applying the chi - square test, those found statistically significant in our study. This suggests that there is a significant difference in the presence of a notch on the right and left side. While Mamatha et al<sup>2</sup>, Hina B. Rajput et al<sup>1</sup> had found it to be insignificant. They found notch 80% and 84% on the right side and 76% and 85% on the left side respectively. Prescher and Klumpen<sup>8</sup> had observed that 45% of the glenoids did not have a notch.

Hina B. Rajput<sup>1</sup> comprised oval glenoids only about 16% on the right side and 15% on the left side. As compared to Mamatha et al<sup>2</sup> who found it

to be 20% on the right side and 24% on the left side. Prescher and Kulmpen<sup>8</sup> observed that 45% of the glenoids were oval shaped. In the study of eighty eight shoulders were taken. Coskun N, et al<sup>9</sup> studied 90 scapulae and found that, in 72% of the specimens, the glenoid notches of the scapulae were absent or oval shaped, whereas in 28% the notch was well expressed and the glenoid cavity was pear shaped. These findings were higher than that of the current findings.

Hence the anatomical basis and variations of shape and size of glenoid cavity of scapula is of fundamental importance in understanding of rotator cuff disease, shoulder dislocation and to decide the proper size of the glenoid component in the shoulder arthroplasty. More and more studies should be done for better knowledge of the anatomy of the scapula to adjust the design and placement of the reverse prosthesis and minimize Scapular notching.

## REFERENCES

- [1]. Hina B Rajput<sup>1</sup>, Kintu K Vyas<sup>1</sup>, Bhavesh D Shroff<sup>2</sup> a study of morphological patterns of glenoid cavity of scapula. National journal of medical research 2 (4), 2012, 504-507.
- [2]. Mamatha T, Pai S R, Murlimanju BV, Kalthur SG, Pai MM, Kumar B. Morphometry of glenoid cavity. Online J Health Allied Scs. 10(3), 2011, 7.
- [3]. Breathnach AS. Frazer's Anatomy of the Human Skeleton. London: J and A Churchill Ltd; 1965, 6, 63-70.
- [4]. Anetzberger H, Putz R. The scapula: principles of construction and stress. *Acta Anat Basel* 156, 1996, 70-80.
- [5]. Inui H, Sugamoto D, Miyamoto T, et al. Evaluation of three-dimensional glenoid structure using MRI. *J Anat.* 199, 2001, 323-328.
- [6]. Burkhart SS, De Beer JF. Traumatic glenohumeral bone defects and their relationship to failure of arthroscopic Bankart repairs: significance of the inverted-pear glenoid and the humeral engaging Hill-Sachs lesion. *Arthroscopy* 16, 2000, 677-694.
- [7]. Kavita P. at all morphology of coracoid process and glenoid cavity in adult human Scapulae. International journal of analytical, pharmaceutical and biomedical sciences 2 (2), 2013, 19-22.
- [8]. Prescher A, Klumpen T. The glenoid notch and its relation to the shape of the glenoid cavity of the scapula. *JAnat.* 190, 1997, 457-460.
- [9]. Coskun N, Karaali K, Can Cevikol C, Bahadir M, Demirel BM, Sindel M. Anatomical basics and variations of the scapula in Turkish adults. *Saudi Med J.* 27(9), 2006, 1320-1325.

**How to cite this article:** Rachna Agrawal, Sangita chauhan, Sunny yadav , Arpita gupta, Manish singhal. Morphological study of shape of glenoid cavity of scapula. Int J of Allied Med Sci and Clin Res 2016; 4(3): 332-336.

**Source of Support:** Nil. **Conflict of Interest:** None declared.